
Mapping of Expressive Language Cortex using Magnetic Source Imaging

Eduardo M. Castillo, Panagiotis G. Simos, Vijay Venkataraman¹, Joshua I. Breier, James W. Wheless¹ and Andrew C. Papanicolaou

Departments of Neurosurgery and ¹Neurology, Vivian L. Smith Center for Neurologic Research, The University of Texas Medical School, Houston, Texas, USA

Abstract

The accurate localization of primary language cortex is one of the goals in the evaluation of brain surgery candidates. In this paper we describe the localization of expressive language cortex using magnetic source imaging (MSI) in a patient with refractory epilepsy caused by a tumor affecting the left inferior frontal gyrus. The magnetoencephalographic recordings during an expressive language task were co-registered with a magnetic resonance imaging (MRI) scan obtained after subdural grid placement and provided a cluster of sources of brain activation in the vicinity of the lesion. This map of expressive language provided by MSI was verified with electrocortical stimulation before the operation. No speech problems were reported in our patient after the resection of the lesion, suggesting that MSI is an accurate non-invasive method for the pre-surgical mapping of expressive language in cases where there is clear functional risk during tumor resection.

Introduction

The identification of cortex specialized for language functions can facilitate surgical planning and reduce the risk of morbidity associated with resection of eloquent cortex, especially in cases of tumors and medically intractable epilepsy. Such knowledge is traditionally sought through invasive procedures like the intracarotid sodium amobarbital perfusion test (Wada test; Strauss and Wada, 1983; Loring *et al.*, 1990) and direct cortical stimulation (Ojeman *et al.*, 1989). In a series of studies (Simos *et al.*, 1998a, b; Papanicolaou *et al.*, 1999) we have shown that identification of the location and extent of cortical regions specialized for receptive language functions can be achieved using magnetic source imaging (MSI). In these studies, receptive language-specific brain activation maps were obtained in the context of simple word recognition tasks, and the accuracy of MSI-based localization was comparable with that of electrocortical stimulation mapping. In this paper we describe the first application of MSI for mapping cortex specialized for expressive language functions using a picture naming task to evoke cortical responses.

Case description

The patient was an 18-year-old left-handed male referred for MSI assessment as part of a phase I epilepsy surgery

evaluation. The onset of his seizure disorder was 16 months ago and was refractory to treatment with multiple anti-epileptic drugs. He underwent pre-surgical evaluation consisting of neurological, neuropsychological and neuro-radiological assessment, as well as scalp video-EEG recordings. Interictally, frequent, and at times continuous focal epileptiform discharges were detected over the left frontal region. Ictal scalp recordings showed diffuse electroencephalographic onset of seizures with no lateralizing features. His intellectual functioning was within the average range with some reduction in controlled oral verbal fluency. A comprehensive neurological examination did not reveal any focal abnormalities.

The Wada test revealed bilateral language representation (right greater than left) and bilateral intact memory. The magnetic resonance imaging (MRI) scan performed previous to the MSI evaluation revealed a non-enhancing lesion on the left frontal operculum, close to Broca's area (Fig. 1a). Receptive language mapping using MSI was performed [for details about this procedure see Breier *et al.* (1999) and Simos *et al.* (1998a)] showing bilateral representation of receptive language. Frontal activation was not detected during this procedure.

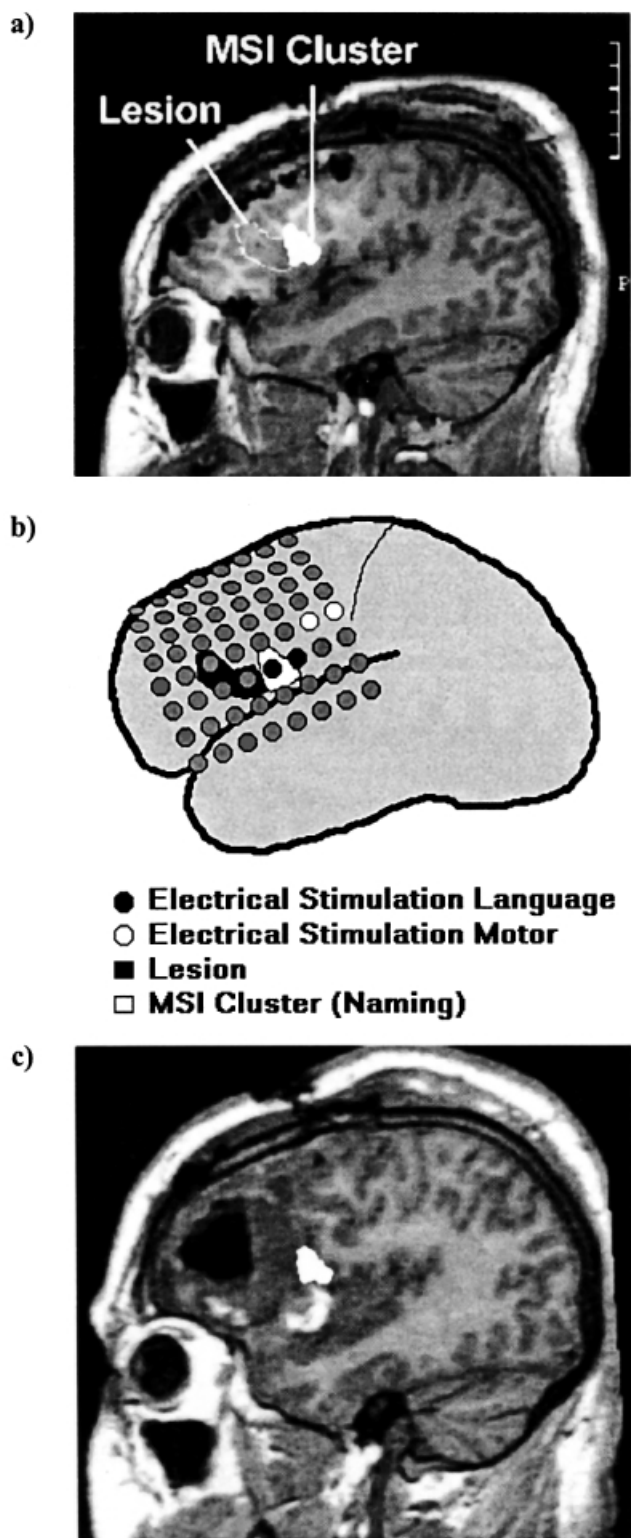


Fig. 1. (a) Clusters of magnetic source imaging (MSI)-derived activity sources projected on the magnetic resonance imaging (MRI) scan after grid placement. (b) Representation of the lesion location, site of effective electrical stimulation (contacts 21–22 for expressive language, contacts 30–31 for right face/tongue twitching; with contact 1 lying anterior inferior, contact 8 lying posterior inferior, contact 57 lying anterior superior and contact 64 lying posterior superior) and clusters of MSI-derived activity sources obtained during the picture naming task (c) Activity sources projected on the MRI after surgery.

Materials and methods

As part of the pre-surgical evaluation protocol, the patient underwent MSI evaluation in the context of two replications of a picture naming task. The MSI was performed using the Magnes 2500 whole head neuromagnetometer (4-D Neuroimaging, San Diego, CA, USA). This device is placed in a magnetically shielded room designed to reduce environmental magnetic noise that interferes with the physiological signals. The stimuli were 140 pictures (black line drawings on a white background) of common objects presented using an LCD projector (JVC-LXD1000U) driven by a Macintosh G4 Powerbook (Apple Computers, Cupertino, CA, USA). The duration of stimulus exposure was 1.2 s and the interstimulus interval (onset-to-onset) varied randomly between 3 and 5 s across trials. The stimuli were projected on a white screen located approximately 1.5 m in front of the participant and subtended 2–4° of visual angle. The patient was asked to name aloud each picture after it disappeared from the screen in order to avoid muscle artefacts. The same task was administered twice in order to ensure the replicability of the MSI maps.

The magnetoencephalographic (MEG) signal was filtered on-line with a band-pass filter between 0.1 and 50 Hz and digitized at a sampling rate of 250 Hz starting 150 ms before the onset of the stimulus. Brain magnetic responses evoked by single picture stimuli were averaged, after removing those epochs with artefacts, resulting in a waveform containing a sequence of event-related fields (ERFs) (Fig. 2). The intracranial sources of the late activity (150–1000 ms) were fitted at successive 4 ms intervals using a non-linear algorithm that searches for the single equivalent current dipole (ECD) that most likely produced the observed magnetic field distribution at a given point in time. Early activity sources are typically localized in modality-specific cortices and are presumably related to primary sensory processing of the stimulus. Previous research has shown that systematic task- and hemisphere-specific effects are only found for 'late' activity sources (i.e. those computed after 150 ms following stimulus onset) (Papanicolaou *et al.*, 1999). For a given point in time, the ECD fitting algorithm was applied to the magnetic flux measurements obtained from a group of 34–38 magnetometers, always including both magnetic flux extrema. ECD solutions were considered as satisfactory if they were associated with a correlation coefficient of at least 0.90 of the observed and the 'best' predicted magnetic field distribution. Subsequently, clusters of activity sources observed reliably during the MSI testing in the context of both replications of the picture naming task were superimposed on MRI scans acquired after grid placement (Fig. 1b). The precise location of the patient's head with respect to the MEG sensors was determined electronically using a Cartesian coordinate system anchored on the same three head landmarks (fiducial points) that define the coordinate system for the MRI. During the data analysis, the fiducial points were identified in the MRI and both coordinate systems were co-registered. This co-

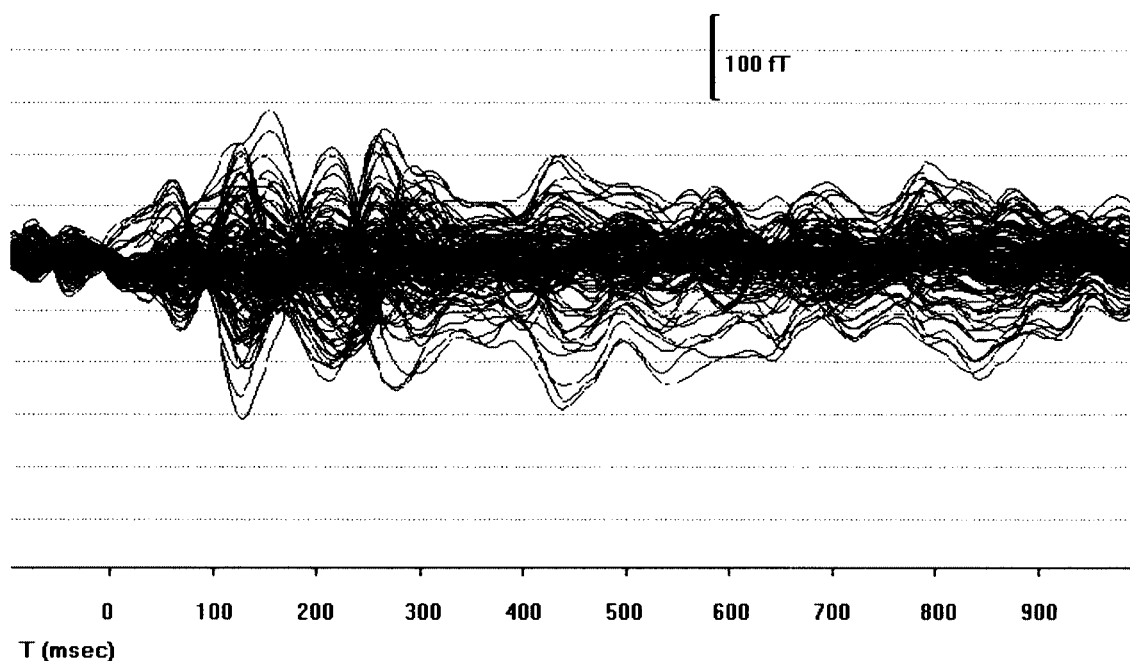


Fig. 2. Representative magnetic source imaging (MSI) waveform: event-related field (ERF) waveform recorded in the context of the picture naming task. Intracranial sources that accounted for the recorded distribution of magnetic flux were computed separately in each hemisphere at 4 ms intervals during the late (after 150 ms) portion of the ERF.

registration system and a 0.9 cut-off for the correlation of the ECD ensured a satisfactory estimation of spatial location of each source. This procedure for precise co-registration of ECD coordinates on structural, T1-weighted, MRI scans (TR = 13.6 ms, TE = 4.8 ms, recording matrix 256×256 pixels, 1 excitation, 240 mm field of view and 1.4 mm slice thickness) and further details about analysis are described in detail elsewhere (Simos *et al.*, 1998a).

In order to verify the accuracy of the MSI-derived maps and prior to resection the patient underwent electrical stimulation mapping.

Stimulation mapping procedure

The patient underwent an initial craniotomy for placement of a 64-contact grid covering a major part of the lateral surface of the frontal lobe (Fig. 1b) and was returned to the epilepsy monitoring unit where cortical stimulation with simultaneous EEG recordings was performed.

A bipolar cortical stimulation study was performed for speech and motor mapping using a Grass S-12 stimulator. The patient was tested for both naming and repetition. He was asked to repeat sentences and simultaneous stimulation was administered for each contact after the initiation of each repetition.

Stimulus parameters were as follows: square-wave pulses of 500 μ s in duration per phase at 50 Hz and a train duration of 5 s. Stimulation intensities of up to 11.5 mA, or to the point of after discharge, were used. All contacts of the 64-contact subdural grid, numbering 1–48 in rows of eight, were stimulated. Stimulation of contacts 21 and 22 produced mild expressive speech deficits with an inability to perform

sentence repetition. Contacts 30 and 31 were stimulated producing right face/tongue twitching during the entire duration of the stimulation. No after discharges were noted. No speech problems were noted with stimulation of the remaining 46 contacts that were tested. MSI clusters of activity were previously located underneath grid contact 21, in the posterior vicinity of the lesion. The overlap between the clusters of MSI-derived language-specific sources with the site associated with language deficits during cortical stimulation mapping is apparent in Fig. 1b.

The patient underwent surgical resection of the lesion sparing the eloquent cortex identified by MSI and verified with electrical stimulation (Fig. 1c). No speech problems were reported after this procedure. The patient's bilateral language representation can account partially for the excellent outcome.

Discussion

Electrocortical stimulation is the actual 'gold standard' method for the accurate localization of eloquent cortex in the pre-surgical evaluation of brain tumor patients (Morris *et al.*, 1986; Ojeman *et al.*, 1989). This can be performed either in the operating room after craniotomy under local anesthesia or extra-operatively via implanted subdural grids. As evidenced by Ojeman *et al.*'s extensive intra-operative studies, the location of language areas varies considerably between individuals over a wide area of cortex (Ojeman *et al.*, 1989). In the case presented here, an anatomic malformation in the vicinity of the inferior frontal gyrus required precise identification of the location and extent of cortex specialized for expressive language function. Express-

ive language cortex was reliably activated during the course of a picture naming task and mapped non-invasively through MSI in the same way that has been previously described for receptive language (Papanicolaou *et al.*, 1999). At least one previous study has reported frontal activation previous to the articulatory response during a picture naming task using MSI (Salmelin *et al.*, 1994). In similar experimental conditions the dynamics of cortical activation during picture naming has been described in healthy subjects using MSI (Levelt *et al.*, 1998). Using other neuroimaging techniques, various studies have proposed the mechanisms engaged by picture naming (Damasio *et al.*, 1996; Price *et al.*, 1996), but these studies have failed to find frontal activation.

MSI provided an easy and safe procedure to characterize the cortical representation of expressive language function that agreed perfectly with electrocortical stimulation.

Conclusion

The verification of the maps provided by the MSI through electrical stimulation mapping and the positive outcome of the patient reaffirm the validity of this approach in the pre-surgical functional mapping of expressive language cortex. Further development of this procedure may increase the accuracy of routine pre-surgical mapping in tumor patients.

Acknowledgement

The research presented in this report was partly supported by NIH grant ROI N537941 to A.C.P.

References

- Breier JI, Simos PG, Zouridakis G, Wheless JW, Willmore LJ, Constantinou JE *et al.* Language dominance determined by magnetic source imaging: a comparison with the Wada procedure. *Neurology* 1999; 53: 938–45.
- Damasio H, Grabowski TJ, Tranel D, Hichwa RD, Damasio AR. A neural basis for lexical retrieval. *Nature* 1996; 380: 499–505.
- Levelt WJ, Praamstra P, Meyer AS, Helenius P, Salmelin R. An MEG study of picture naming. *Journal of Cognitive Neuroscience* 1998; 10: 553–67.
- Loring DW, Meador KL, Lee GP. Cerebral language lateralization: evidence from intracarotid amobarbital testing. *Neuropsychologia* 1990; 28: 831–8.
- Morris HH, Luders H, Hahn JF, Lesser RP, Dinner DS, Estes ML. Neurophysiological techniques as an aid to surgical treatment of primary brain tumors. *Annals of Neurology* 1986; 19: 559–67.
- Ojeman G, Ojeman J, Lettich E, Burger M. Cortical language localization in left dominant hemisphere: An electrical stimulation mapping investigation in 117 patients. *Journal of Neurosurgery* 1989; 71: 316–26.
- Papanicolaou AC, Simos PG, Breier JI, Zouridakis G, Willmore LJ, Wheless JW *et al.* Magnetoencephalographic mapping of the language-specific cortex. *Journal of Neurosurgery* 1999; 90: 85–93.
- Price CJ, Moore CJ, Humphreys GW, Frackowiak RSJ, Friston KJ. The neural regions sustaining object recognition and naming. *Proceedings of the Royal Society of London B* 1996; 263: 1501–7.
- Salmelin R, Hari R, Lounasmaa OV, Sams M. Dynamics of brain activation during picture naming. *Nature* 1994; 31: 463–5.
- Simos PG, Breier JI, Zouridakis G, Papanicolaou AC. Assessment of functional cerebral laterality for language using magnetoencephalography. *Journal of Clinical Neurophysiology* 1998a; 15: 364–72.
- Simos PG, Breier JI, Zouridakis G, Papanicolaou AC. Identification of language-specific brain activity using magnetoencephalography. *Journal of Clinical and Experimental Neuropsychology* 1998b; 20: 705–22.
- Strauss E, Wada J. Lateral preferences and cerebral speech dominance. *Cortex* 1983; 19: 165–77.

Received 26 March, 2001; resubmitted 24 June, 2001; accepted 25 June, 2001

Mapping of expressive language cortex using magnetic source imaging

E. M. Castillo, P. G. Simos, V. Venkataraman, J. I. Breier, J. W. Wheless and A. C. Papanicolaou

Abstract

The accurate localization of primary language cortex is one of the goals in the evaluation of brain surgery candidates. In this paper we describe the localization of expressive language cortex using magnetic source imaging (MSI) in a patient with refractory epilepsy caused by a tumor affecting the left inferior frontal gyrus. The magnetoencephalographic recordings during an expressive language task were co-registered with a magnetic resonance imaging (MRI) scan obtained after subdural grid placement and provided a cluster of sources of brain activation in the vicinity of the lesion. This map of expressive language provided by MSI was verified with electrocortical stimulation before the operation. No speech problems were reported in our patient after the resection of the lesion, suggesting that MSI is an accurate non-invasive method for the pre-surgical mapping of expressive language in cases where there is clear functional risk during tumor resection.

Journal

Neurocase 2001; 7: 419–22

Neurocase Reference Number:

O233

Primary diagnosis of interest

Brain tumor

Author's designation of case

The patient

Key theoretical issue

- The application of magnetic source imaging for mapping cortex specialized for expressive language functions

Key words: magnetic source imaging; language mapping; electrical stimulation

Scan, EEG and related measures

Magnetic source imaging

Standardized assessment

Pre-surgical mapping

Lesion location

- Frontal lobe

Lesion type

Tumor

Language

English