



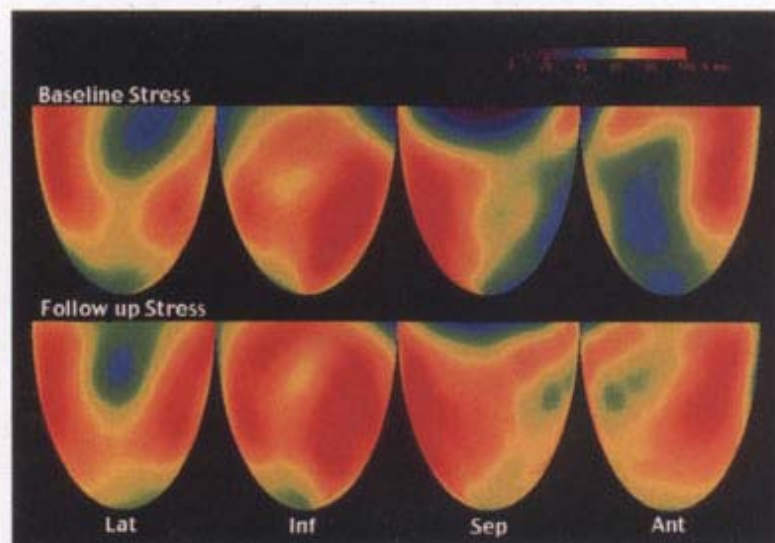
January 15, 2003

Volume 41

Number 2

Journal of the

American College *of* Cardiology



Three-dimensional topographic dipyridamole PET with improved perfusion following treatment. Upper row is baseline and lower row at follow-up. Red is highest flow and blue is lowest.